

Floating norms for the assessment of craniofacial pattern in the deciduous dentition

Isabella Tollaro, Tiziano Baccetti and Lorenzo Franchi

Department of Orthodontics, University of Florence, Italy

SUMMARY This study provides norms for the evaluation of individual skeletal patterns in subjects with full deciduous dentition. The method is based on the associations among correlated craniofacial measurements (S–N–A, S–N–B, NL–NSL, ML–NSL, N–S–Ba). The results are given in a graphical box-like form (floating norms). An easy practical procedure allows identification of either individual harmonious craniofacial features or anomalous deviations from the individual norm. The use of cephalometric floating norms in the deciduous dentition phase is strongly recommended for early diagnosis and treatment planning.

Introduction

Conventional cephalometric diagnosis is clinically based on the use of population mean and range for separated craniofacial measurements. However, significant correlations among cephalometric skeletal variables (topographical correlations) have been assessed (Solow, 1966). This finding led to the concept of craniofacial pattern, which can be described by correlated sagittal and vertical skeletal parameters. It appeared advantageous therefore to substitute the norm intended as a population mean with a new norm constructed on the variability of the associations among suitable cephalometric variables (floating norms) (Hasund and Bøe, 1980; Järvinen, 1986; Segner, 1989).

Unfortunately, floating norms as a means to evaluate individual skeletal patterns have been developed only for adult subjects (Segner, 1989). An attempt to provide a cephalometric classification of facial patterns for a sample of untreated subjects aged 7–19 years using floating norms was undertaken by Lavergne and Gasson (1976, 1982). This system allowed an appraisal of individual skeletal features during the juvenile and adolescent periods (Petrovic *et al.*, 1987, 1990).

In our opinion, the use of floating norms in earlier developmental phases should also be considered. During the deciduous dentition phase some malocclusions are already evident and they show a distinctive craniofacial pattern (Bishara *et al.*, 1988; Varrela, 1993; Tollaro

et al., 1994). Additionally, early diagnosis is needed in order to start treatment immediately when appropriate (West, 1969; Stensland *et al.*, 1988; Tollaro *et al.*, 1995a,b).

The aim of the present study is to give floating norms for the assessment of individual craniofacial pattern in the deciduous dentition phase as a guidance for early diagnosis and treatment planning.

Subjects and methods

A sample of 100 untreated children (42 males, 58 females) was selected from the files of the Department of Orthodontics of the University of Florence, Italy. All the children presented full deciduous dentition (mean age 5.67 ± 0.82 years).

The subjects were chosen according to the following criteria:

- 1) absence of caries of deciduous teeth;
- 2) absence of congenitally missing deciduous teeth;
- 3) absence of cleft lip and/or palate and of craniofacial malformative syndromes;
- 4) presence of normal occlusal relationship, i.e. flush terminal plane or mesial step deciduous molar relationship, Class I deciduous canine relationship, absence of anterior crossbite and open-bite.

The investigated sample therefore consisted of a group with ideal occlusion. All the subjects

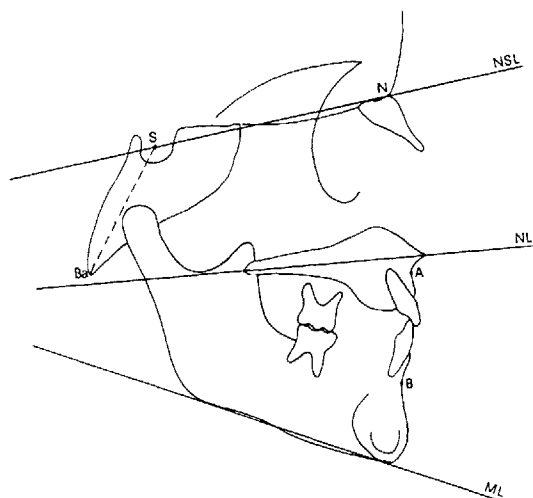


Figure 1 Cephalometric landmarks and planes.

were white Caucasian children from Tuscany, Italy.

Though not required by the nature of the cephalometric measurements (angular measurements), lateral standardized cephalograms of the 100 children were taken by using the same X-ray device and by a single technician. The focus-median plane distance was 152 cm and the film-median plane distance was 10 cm, allowing an enlargement of 7 per cent.

The following measurements were performed (Fig. 1): maxillary prognathism (S-N-A), mandibular prognathism (S-N-B), maxillary

inclination relative to the cranial base (NL-NSL), mandibular inclination relative to the cranial base (ML-NSL) and cranial base angle (N-S-Ba).

The method error for all these angles was assessed by means of Dahlberg's formula (1940) on 20 repeated measurements randomly selected from the total of the observations. The error in degrees was 0.58 for S-N-A; 0.41 for S-N-B; 0.31 for NL-NSL; 0.45 for ML-NSL; and 0.63 for N-S-Ba.

Data analysis

The statistical examination (Statgraphics®, 1987) of the recorded data comprised:

- 1) calculation of Pearson's correlation coefficients;
- 2) linear regression analysis;
- 3) multiple regression analysis.

Results

Descriptive statistics for all the cephalometric measurements are given in Table 1. Table 2 shows the linear correlation coefficients (r) between the cephalometric variables.

Linear regression equations with corresponding r^2 and standard error of the estimate are reported in Table 3. Table 4 shows the multiple

Table 1 Descriptive statistics.

| Cephalometric variables | Mean | SD | SE | Min | Max |
|-------------------------|--------|------|------|-------|-------|
| SNA | 79.88 | 2.91 | 0.29 | 70.5 | 88.5 |
| SNB | 76.35 | 2.85 | 0.28 | 69.0 | 83.5 |
| NL-NSL | 7.94 | 2.75 | 0.27 | -0.5 | 15.0 |
| ML-NSL | 35.23 | 3.27 | 0.32 | 27.5 | 43.0 |
| NSBa | 131.56 | 4.44 | 0.44 | 121.0 | 142.0 |

Table 3 Linear regression equations with corresponding r^2 and standard error (S.E.) of the estimate.

| Regression equations | r^2 | S.E. |
|----------------------------|-------|------|
| SNB = 0.901SNA + 4.26 | 0.84 | 1.11 |
| NL-NSL = -0.387SNA + 38.92 | 0.16 | 2.52 |
| ML-NSL = -0.328SNA + 61.43 | 0.08 | 3.14 |
| NSBa = -0.741SNA + 190.93 | 0.23 | 3.89 |
| SNA = -0.319NSBa + 121.98 | 0.23 | 2.55 |

Table 2 Correlation coefficients (r) between the cephalometric measurements.

| Cephalometric variables | NL-NSL | N-S-Ba | ML-NSL | S-N-B |
|-------------------------|-----------|-----------|----------|-----------|
| S-N-A | -0.409*** | -0.488*** | -0.292** | 0.922*** |
| NL-NSL | | 0.238* | 0.282** | -0.407*** |
| N-S-Ba | | | 0.295** | -0.461*** |
| ML-NSL | | | | -0.384*** |

* $P < 0.05$. ** $P < 0.01$. *** $P < 0.001$.

| S-N-A | NL-NSL | N-S-Ba | ML-NSL | S-N-B |
|-------|--------|--------|--------|-------|
| 58 | | 148 | | 56 |
| 59 | 16 | 147 | 42 | 57 |
| 60 | | 146 | | 58 |
| 61 | 15 | 145 | 41 | 59 |
| 62 | | 144 | | 60 |
| 63 | 14 | 143 | 40 | 61 |
| 64 | | 142 | | 62 |
| 65 | 13 | 141 | 39 | 63 |
| 66 | | 140 | | 64 |
| 67 | 12 | 139 | 38 | 65 |
| 68 | | 138 | | 66 |
| 69 | 11 | 137 | 37 | 67 |
| 70 | | 136 | | 68 |
| 71 | 10 | 135 | 36 | 69 |
| 72 | | 134 | | 70 |
| 73 | 9 | 133 | 35 | 71 |
| 74 | | 132 | | 72 |
| 75 | 8 | 131 | 34 | 73 |
| 76 | | 130 | | 74 |
| 77 | 7 | 129 | 33 | 75 |
| 78 | | 128 | | 76 |
| 79 | 6 | 127 | 32 | 77 |
| 80 | | 126 | | 78 |
| 81 | 5 | 125 | 31 | 79 |
| 82 | | 124 | | 80 |
| 83 | 4 | 123 | 30 | 81 |
| 84 | | 122 | | 82 |
| 85 | 3 | 121 | 29 | 83 |
| 86 | | 120 | | 84 |
| 87 | 2 | 119 | 28 | 85 |
| 88 | | 118 | | 86 |
| 89 | 1 | 117 | | 87 |
| 90 | | 116 | | 88 |
| 91 | 0 | 115 | | 89 |
| 92 | | | | 90 |
| 93 | | | | 91 |
| 94 | | | | 92 |
| 95 | | | | 93 |
| 96 | | | | 94 |
| 97 | | | | 95 |
| 98 | | | | 96 |
| 99 | | | | |
| 100 | | | | |
| 101 | | | | |
| 102 | | | | |
| 103 | | | | |

Figure 2 Floating norms for the deciduous dentition in a graphical box-like form.

Table 4 Standard errors of the estimate (SE) when predicting one of the variables S-N-A, NL-NSL, N-S-Ba, ML-NSL, and S-N-B from the other four by means of multiple regression analysis ($n = 100$).

| Cephalometric variables | R | R^2 | SE |
|-------------------------|------|-------|------|
| SNA | 0.92 | 0.85 | 1.10 |
| NL-NSL | 0.40 | 0.16 | 2.52 |
| NSBa | 0.48 | 0.23 | 3.89 |
| ML-NSL | 0.42 | 0.18 | 2.94 |
| SNB | 0.92 | 0.85 | 1.07 |

correlation coefficients R , the adjusted R^2 and the standard error of the estimate when pre-

dicting one of the five measured variables from the remaining four by means of a multiple regression analysis.

Figure 2 illustrates the regression results in a graphical box-like form with S-N-A as the independent variable and NL-NSL, N-S-Ba, ML-NSL, and S-N-B each as the dependent variable, according to the method of Segner (1989).

Discussion

Many authors have recommended an early orthodontic/orthopaedic approach to different types of malocclusion (Thilander, 1963;

Sakamoto, 1981; Wieslander, 1984; Takada *et al.*, 1993). Moreover, the comparison between the values for some of the cephalometric variables (S-N-A, S-N-B, ML-NSL) in our primary dentition sample and in Segner's permanent dentition sample was statistically significant (Student's *t*-test, $P < 0.01$). This finding justified the investigation into craniofacial skeletal pattern in the deciduous dentition phase, in order to provide a discrete tool for early diagnosis and treatment planning. As no statistically significant differences between males and females were found for any of the cephalometric variables, the data were pooled.

The diagnostic diagram which is presented as a graphical box (Fig. 2) is the outcome of the pattern of associations among cephalometric variables. Any horizontal line connecting the values of the different variables inside the box has to be considered as a line expressing an harmonious skeletal pattern during the deciduous dentition phase. The line may correspond to the centre of the box (Fig. 3). In this case, the subject will be classified as harmonious and orthognathic. In fact, the central line of the box connects the mean values for the various measurements. When the line lies in the upper part of the box, the subject, though still harmonious,

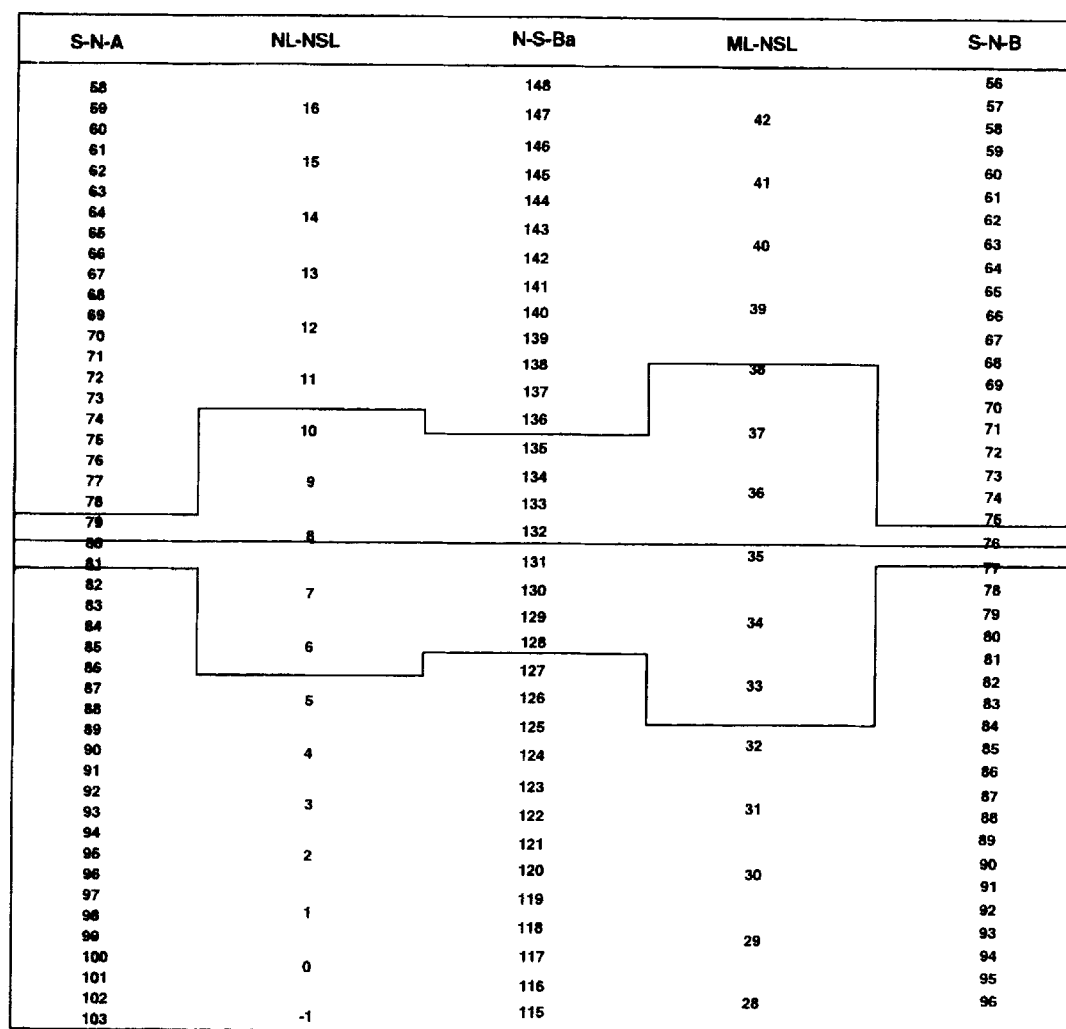


Figure 3 Graphical box with the mid-line connecting the mean values of the cephalometric variables and the range of variability represented by the standard error of the estimate of multiple regression analysis.

is classified as retrognathic. In order to maintain the ideal occlusion, the two jaws have to incline downward and backward in relation to the cranial base. When, on the other hand, the line lies in the lower part of the box, the subject, though still harmonious, is classified as prognathic and the jaws will show an upward-forward inclination in relation to the cranial base. A certain range of variability around any horizontal harmony line is actually allowed. The range of variability is represented by the standard error of the estimate of the multiple

regression analysis (Table 4). It therefore depends on the variability of the associations among cephalometric variables. The range is narrower for S-N-A and S-N-B, and wider for the remaining three variables (Fig. 3). Standard errors of the estimate for all the variables were lower than those given by Segner (1989). In particular, S-N-A, S-N-B and ML-NSL showed a narrower range, probably related to a smaller inter-subject skeletal variability in the deciduous dentition when compared with adult ages.

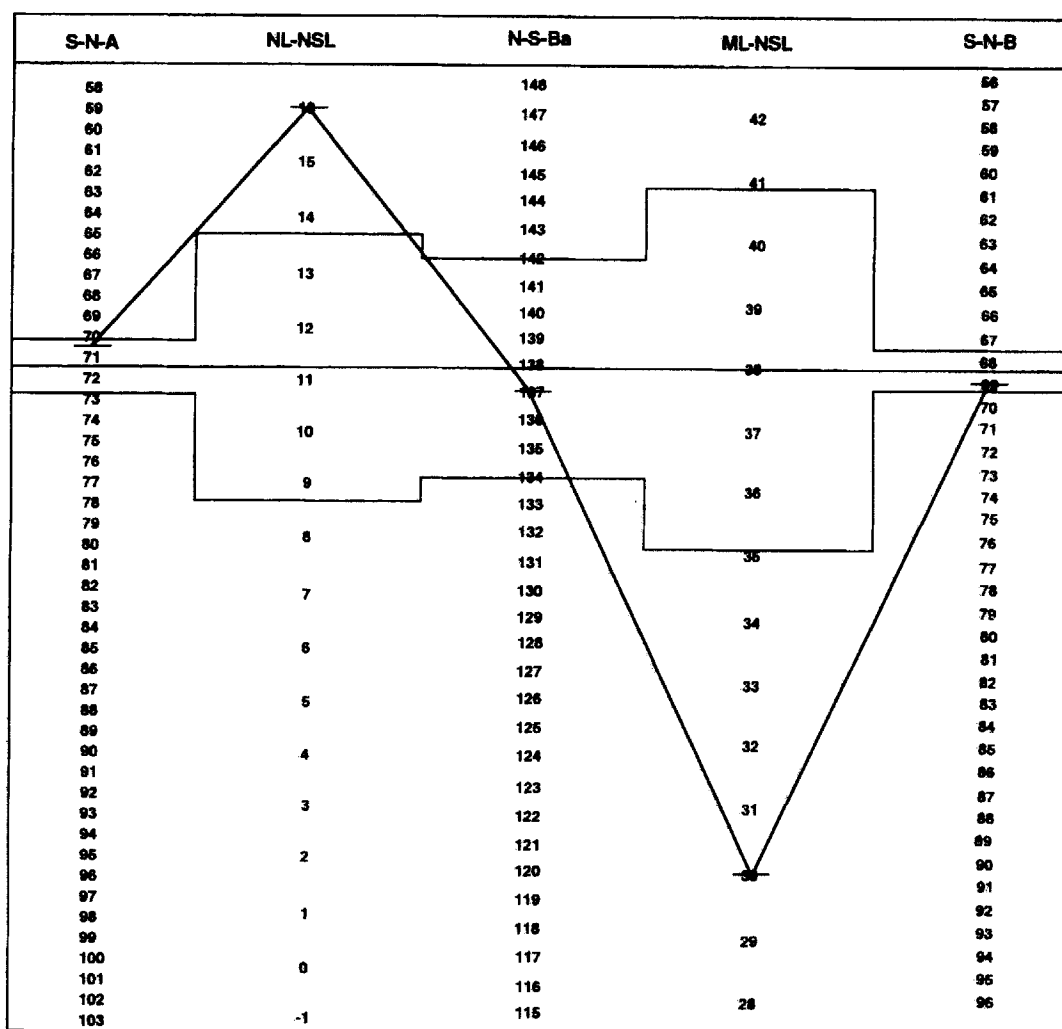


Figure 4 Values for a 5.6-year-old female reported inside the graphical box. The individual harmony line lies in the upper part of the box so that the patient can be classified as retrognathic. All the values except NL-NSL and ML-NSL fall within the range of variability. Consequently, the deviations from the harmonious craniofacial pattern are localized in the inclination of the two jaws in relation to the cranial base.

A subject whose cephalometric values fall within the range can still be considered as a subject endowed with an harmonious skeletal relationship. The same subject will be further classified as ortho-, retro- or prognathic according to the zone of the box that includes his cephalometric values. In this case, the individual horizontal harmony line is traced as a best-fit line among the individual cephalometric values. Practically, the range should be moved inside the box in a way that all the values of the patient fall within the borders of the range.

A step-by-step practical procedure can be performed as follows:

- 1) Localize the five cephalometric values of the patient inside the graphical box (Fig. 2).
- 2) Take a transparent acetate and draw on it only the borders of the range together with the mid-line as they appear in Fig. 3.
- 3) Superimpose the acetate on the graphical box.
- 4) Move the acetate along the graphical box so that the highest number of individual values fall within the range. The mid-line of the range on the acetate will automatically become the best-fit individual harmony line for the patient.
- 5) The value (or the values) which remain outside the range will indicate the deviation from a harmonious craniofacial pattern.

If one or more individual values lie outside of the range, they will indicate deviations from harmonious facial pattern. In this way, the cephalometric variables responsible for an unbalanced skeletal pattern will be easily detected. For example, the subject, a 5.6 year-old female, whose cephalometric values are shown in Fig. 4 presents three out of the five individual measurements within the borders of the range. The individual harmony line which is the best-fit line for the cephalometric measurements, lies in the upper part of the box. This classifies the patient as retrognathic. Further, the subject is harmonious as to sagittal skeletal relationship and to angulation of the cranial base (S-N-A, N-S-Ba, S-N-B). The deviations from harmonious craniofacial pattern are located in the inclinations of the jaws in relation to the cranial base (NL-NSL and ML-NSL). In particular the palatal plane is tilted downward and backward, whilst the mandibular

plane is tilted upward and forward. Consequently, a diagnosis of skeletal deep bite can be assessed in this patient.

The early identification of such a severe skeletal deep bite during the deciduous dentition phase represents an important diagnostic finding allowing treatment to start immediately or to wait for more advanced developmental phases (after eruption of first permanent molars).

The results of the present study emphasize the importance of using a discrete cephalometric reference in the deciduous dentition. Further investigations should assess the possible need for a separate set of floating norms and of a separate box for children in the mixed dentition.

Address for correspondence

Prof. Dr. Isabella Tollaro
Via Fra' Giovanni Angelico, 24
I-50121 Florence, Italy

References

- Bishara S E, Hoppens B J, Jakobsen J R, Kohout F J 1988 Changes in the molar relationship between the deciduous and permanent dentitions: a longitudinal study. *American Journal of Orthodontics and Dentofacial Orthopedics* 93: 19-28
- Dahlberg G 1940 Statistical methods for medical and biological students. Interscience Publications, New York
- Hasund A, Bøe O E 1980 Floating norms as guidance for the position of the lower incisors. *Angle Orthodontist* 50: 165-168
- Järvinen S 1986 Floating norms for the ANB angle as guidance for clinical considerations. *American Journal of Orthodontics and Dentofacial Orthopedics* 90: 383-387
- Lavergne J, Gasson N 1976 A metal implant study of mandibular rotation. *Angle Orthodontist* 46: 144-150
- Lavergne J, Gasson N 1982 Analysis and classification of the rotational growth pattern without implants. *British Journal of Orthodontics* 9: 51-56
- Petrovic A, Lavergne J, Stutzmann J 1987 Diagnostic et traitement en orthopedie dento-faciale: principes et diagramme de decision. *L'Orthodontie Française* 58: 517-542
- Petrovic A, Stutzmann J, Lavergne J 1990 Mechanisms of craniofacial growth and modus operandi of functional appliances: a cell-level and cybernetic approach to orthodontic decision making. In: Carlson D S (ed.) *Craniofacial growth theory and orthodontic treatment*. Monograph 23, Craniofacial Growth Series, Center for Human Growth and Development, University of Michigan, Ann Arbor, pp. 13-74
- Sakamoto T 1981 Effective timing for the application of orthopedic force in the skeletal Class III malocclusion. *American Journal of Orthodontics* 80: 411-416

- Segner D 1989 Floating norms as a means to describe individual skeletal patterns. *European Journal of Orthodontics* 11: 214–220
- Solow B 1966 The pattern of craniofacial associations. A morphological and methodological correlation and factor analysis study on young adults. *Acta Odontologica Scandinavica*, 24: Supplement 46
- Statistical Graphics Corporation 1987 'Statgraphics® version 2.6'. MD STSC Inc., Rockville, USA
- Stensland A, Wisth P J, Bøe O E 1988 Dentofacial changes in children with negative overjet treated by a combined orthodontic and orthopaedic approach. *European Journal of Orthodontics* 10: 39–51
- Takada K, Petdachai S, Sakuda M 1993 Changes in dentofacial morphology in skeletal Class III children treated by a modified maxillary protraction headgear and a chin cup: a longitudinal cephalometric appraisal. *European Journal of Orthodontics* 15: 211–222
- Thilander B 1963 Treatment of Angle Class III malocclusion with chin-cap. *Transactions of the European Orthodontic Society*, pp 384–398
- Tollaro I, Baccetti T, Bassarelli V, Franchi L 1994 Class III malocclusion in the deciduous dentition: a morphological and correlation study. *European Journal of Orthodontics* 16: 401–408
- Tollaro I, Baccetti T, Franchi L 1995a Mandibular skeletal changes induced by early functional treatment of Class III malocclusion: a superimposition study. *American Journal of Orthodontics and Dentofacial Orthopedics* (in press)
- Tollaro I, Baccetti T, Franchi L 1995b Craniofacial changes induced by early functional treatment of Class III malocclusion. *American Journal of Orthodontics and Dentofacial Orthopedics* (in press)
- Varrela J 1993 Longitudinal assessment of Class II occlusal and skeletal development in the deciduous dentition. *European Journal of Orthodontics* 15: 345 (Abstract)
- West E E 1969 Treatment objectives in the deciduous dentition. *American Journal of Orthodontics* 55: 617–632
- Wieslander L 1984 Intensive treatment of severe Class II malocclusion with a headgear-Herbst appliance in the early mixed dentition. *American Journal of Orthodontics* 86: 1–13